

A Case of Aspergillosis in a Broiler Breeder Flock

Author(s): Mehmet Akan, Rıfki Hazıroğlu, Ziya İlhan, Barış Sareyyüpoğlu, and Recai Tunca

Source: Avian Diseases, 46(2):497-501.

Published By: American Association of Avian Pathologists

DOI: [http://dx.doi.org/10.1637/0005-2086\(2002\)046\[0497:ACOAIA\]2.0.CO;2](http://dx.doi.org/10.1637/0005-2086(2002)046[0497:ACOAIA]2.0.CO;2)

URL: <http://www.bioone.org/doi/full/10.1637/0005-2086%282002%29046%5B0497%3AACOAIA%5D2.0.CO%3B2>

BioOne (www.bioone.org) is a nonprofit, online aggregation of core research in the biological, ecological, and environmental sciences. BioOne provides a sustainable online platform for over 170 journals and books published by nonprofit societies, associations, museums, institutions, and presses.

Your use of this PDF, the BioOne Web site, and all posted and associated content indicates your acceptance of BioOne's Terms of Use, available at www.bioone.org/page/terms_of_use.

Usage of BioOne content is strictly limited to personal, educational, and non-commercial use. Commercial inquiries or rights and permissions requests should be directed to the individual publisher as copyright holder.

Case Report—

A Case of Aspergillosis in a Broiler Breeder Flock

Mehmet Akan,^A Rıfki Hazıroğlu,^B Ziya İlhan,^A Barış Sareyyüpoğlu,^A and Recai Tunca^B

^ADepartment of Microbiology

^BDepartment of Pathology

Veterinary Faculty, University of Ankara, Dışkapı, Ankara, Turkey

Received 17 August 2001

SUMMARY. A case of aspergillosis in a broiler breeder flock having respiratory and nervous system problems caused by *Aspergillus fumigatus* and *Aspergillus niger* is documented. Dyspnea, hyperpnea, blindness, torticollis, lack of equilibrium, and stunting were observed clinically. On postmortem examination of the affected birds, white to yellow caseous nodules were observed on lungs, thoracic air sacs, eyes, and cerebellum. Histopathologic examination of lungs and cerebellum revealed classic granulomatous inflammation and cerebellar lesions, necrotic meningoencephalitis, respectively. No lesions were noted in the cerebrum histopathologically. *Aspergillus* hyphae were observed in stained sections prepared from lesioned organs. Fungal spores and branched septate hyphae were observed in direct microscopy. *Aspergillus fumigatus* and *A. niger* were isolated from the inoculations prepared from the suspensions of organs showing lesions.

RESUMEN. *Reporte de Caso*—Un caso de Aspergillosis en un lote de reproductoras de engorde.

En un lote de reproductoras de engorde con problemas respiratorios y nerviosos se documenta un caso de Aspergillosis causado por *Aspergillus fumigatus* y *Aspergillus niger*. Clínicamente se observó disnea, hipernea, ceguera, torticollis, pérdida del equilibrio y enanismo. A la necropsia de las aves afectadas se observaron nódulos caseosos blancos o amarillos en los pulmones, sacos aéreos, ojos y cerebelo. El examen histopatológico de los pulmones y del cerebelo reveló una inflamación granulomatosa clásica y lesiones cerebelares y meningoencefalitis necrótica, respectivamente. Por histopatología no se observaron lesiones en el cerebro. Se observaron hifas de *Aspergillus* en las secciones teñidas de los tejidos afectados. Al examen microscópico directo se observaron los esporos de hongos e hifas septadas. Se aisló el *Aspergillus fumigatus* y el *Aspergillus niger* de las suspensiones de los órganos afectados.

Key words: aspergillosis, *Aspergillus fumigatus*, *Aspergillus niger*, broiler breeders, cerebellar lesions

Abbreviations: GMS = Gomori methenamine silver; H&E = hematoxylin and eosin; KOH = potassium hydroxide; PAS = periodic acid–Schiff

Aspergillosis is an important mycotic disease that affects many species of birds, including poultry. Although the term “aspergillosis” usually refers to pulmonary aspergillosis (lung or air sac), the disease is also manifested as systemic, ophthalmic, or encephalitic syndromes. It also affects the skin or bone (12). Outbreaks of disease due to various species of *Aspergillus* are common in chicks and poults. *Aspergillus fumigatus* is the species most commonly isolated from poultry. However, *Aspergillus flavus* and

other species also have been reported from both chickens and turkeys (3,7,12). *Aspergillus niger* and *A. flavus* were isolated in a dual pulmonary aspergillosis infection from 3-to-8-wk-old ostriches in Israel (10).

The present paper documents a case of aspergillosis concurrently caused by *A. fumigatus* and *A. niger* in broiler breeder pullets in which the fungal colonization was confined to lungs, eyes, thoracic air sacs, and cerebellum.




Fig. 1. Lateral recumbency and chick is not standing.

CASE REPORT

Case history. In a period of 8 wk, 48 live broiler pullets from a broiler breeder farm of 15,000 capacity were presented for necropsy to the Avian Diseases Diagnostic Laboratory of the Department of Microbiology, Veterinary Faculty, University of Ankara, on weekly intervals from three houses of a ranch that consisted 5000 pullets each. Birds showing disease symptoms ranged in age between 2 and 10 wk. The birds were bred in lighting and temperature controlled houses with floor litter of wood shavings and were fed by floor feeding after they were 4 wk old. Whereas water and feed were given *ad libitum* for the first 3 wk, after the third week, feed allowances of birds were controlled in order to achieve target body weights. Variable mortalities were observed among the houses with the ratios 4.1%, 4.5%, and 5.6%, respectively, with an average mortality of 4.7%. Mortality in the flocks reached a peak in the fourth to fifth weeks, and by the 10th week it declined below 0.01%. During the 10-wk period, birds were vaccinated against infectious bronchitis, Newcastle disease, and infectious bursal disease. Vaccination against in-

fectious bronchitis by coarse spray was carried out on day 1 and the other vaccinations were added to the drinking water.

The affected poultts exhibited dyspnea, hyperpnea, blindness, central nervous system disorders such as torticollis, lack of equilibrium, ataxia, and lateral recumbency, and stunting clinically. Some of the 48 breeder poultts submitted had unilateral and/or bilateral periorbital swelling, turbid discharge from the eye, eyelids that were swollen and adhered together, and cheesy yellow exudate within the conjunctival sac. During clinical investigation, various degrees of paralysis were observed. Some birds showed ataxia, others sat on their hocks, and some lay on their sides. Many birds were found in lateral recumbency (Fig. 1).

Necropsy. On necropsy, gross lesions were observed in the eyes, lungs, thoracic air sacs, and cerebellum. Small yellowish-white caseous nodules were scattered throughout lung tissue and yellow caseous plaques were observed on thoracic air sacs. Eighteen chickens had advanced cases showing larger and numerous plaques on greatly thickened air sac membranes, and the plaques coalesced to form ag-

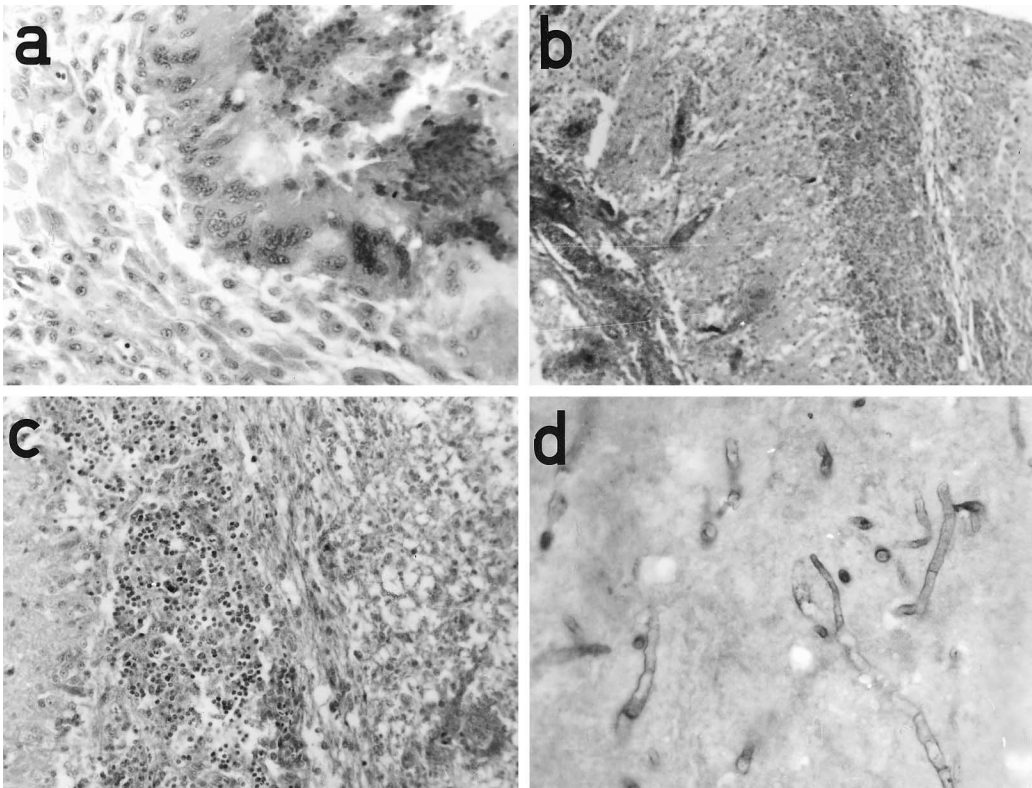


Fig. 2. (a) Note heterophils and giant cells in the granuloma. H&E. 480 \times . (b) Mycotic encephalomalacia. Cerebellum showing extensive encephalomalacia. Edema and pyknosis of the granular layer, capillary hemorrhages, and thrombosis. H&E. 120 \times . (c) Close view of the cerebellum. Pyknosis of the granular layer is clearly seen on left. White matter on the right shows malacia. H&E. 240 \times . (d) *Aspergillus* spp. hyphae in the cerebellum. PAS. 480 \times .

gregate lesions. Fourteen chickens had white to yellow circumscribed areas in their cerebellums.

Histopathologic examination. The tissues with lesion were fixed in 10% formalin. Later, they were cut 5–6 μm in thickness and stained by hematoxylin and eosin (H&E), periodic acid–Schiff (PAS), and Grocott–Gomori methenamine silver (GMS) techniques (6).

Histologically, the lesions in lungs were characterized by well demarcated foci of necrosis with infiltration by heterophils, macrophages, and giant cells (Fig. 2a). Fungal hyphae were clearly demonstrated in the lungs and cerebellum (Fig. 2d) by GMS and PAS stains, respectively.

Microscopically, edema and pyknosis of the granular layer, capillary hemorrhages, and hyaline thrombosis (Fig. 2b) were observed in the cerebellum. Additionally, encephalomalacic foci with associated inflammatory reaction were also

detected (Fig. 2c). In many areas, the meninges of the cerebellum were heavily infiltrated with heterophils and mononuclear cells.

Microbiologic examination. Lactophenol cotton mounts were prepared from the lesions that existed in the organs. Suspensions of the organs showing lesions were examined microscopically after having been treated with 15% potassium hydroxide (KOH) for 10 min, and inoculations were made from the suspensions to two series of blood agar (Oxoid, Basingstoke, Hampshire, U.K.) and Sabouraud dextrose agar (Oxoid) supplemented with chloramphenicol (0.05 mg/ml). Cultures were incubated aerobically at 25 C and 37 C for 5–7 days. Suspensions of lesioned organs in KOH preparations showed dichotomously branched septate hyphae, characteristic of *Aspergillus* species. *Aspergillus fumigatus* and *A. niger* were isolated on Sabouraud dextrose agar. The isolates revealed

typical conidiophores with clavate vesicles and uniseriate sterigmata bearing chains of conidia in lactophenol cotton blue mounts.

In order to establish the source of infection, nine samples of litter and six samples of feed were also screened for the pathogen by dilution technique. The average numbers of fungi found were $1.3 \times 10^4/g$ in litter and $2.3 \times 10^3/g$ in feed.

DISCUSSION

Aspergillus fumigatus is the most common etiologic agent in cases of aspergillosis (12). Aspergillosis can occur as an acute disease with high morbidity and mortality in young birds, or it can occur as a chronic disease, affecting fewer numbers of older birds, particularly tom turkeys (2). Clinical signs such as dyspnea, gasping, cyanosis, and hyperpnea are usually associated with aspergillosis (12). In the present case, although signs resembling respiratory disease were observed, clinical signs intensively in central nervous system and eyes were noted. A stunting in the birds was also observed.

Richard and Thurston (13) reported that *A. fumigatus* and *A. flavus* were isolated from systemic blood after aerosol exposure to spores of these agents. In the present case, all three flocks could have been exposed to large numbers of fungal spores. Immunosuppression of individual birds could have allowed opportunistic fungi to colonize the respiratory tract. Okoye *et al.* (8) noted that infectious bursal disease can increase the severity of *A. flavus* infection. In the present case, the chronic course of disease may be due to a continuous contamination with the *Aspergillus* spores in the litter and immunosuppression in birds. Barton *et al.* (2) reported that spray vaccination against infectious bursal disease, infectious bronchitis, and Newcastle disease was suggested as a likely contributing factor. In the present chronic case of disease, stress factors such as intensive vaccinations, debeaking, and the higher number of chicks having a low body weight were thought to contribute to disease.

Aspergillus spp. infection typically produces fungal nodules or plaques within the lungs and on the air sacs. Occasionally, the trachea and syrinx are also affected (9,12). In the present report, air sacs, lungs, eyes, and brain were affected macroscopically. Lesions were observed

as small white to yellow caseous nodules. In the histopathologic examinations, the lesions in lung were characterized by well demarcated foci of necrosis with infiltration by heterophils, macrophages, and giant cells. In brain, lesions were detected malacic in nature.

Feed and litter on poultry farms are important reservoirs of *Aspergillus* spp., and inhalation of fungal spores dispersed from moldy feed, litter, meal, grains, etc. causes the disease (4,5,14,15,16). In the present case, concerning the investigation results of feed and litter, although total fungus counts in the feed were acceptable according to the standards in Turkey, litter was heavily contaminated with *Aspergillus* spp. The method of application of feed (floor feeding) after the fourth week caused birds to feed from the contaminated litter. Immunosuppression in the first week of brooding period caused by debeaking, stress factors such as intensive vaccinations, and low body weight gains might have contributed to the infection.

The presence of these organisms in the lungs, cerebellum, and cerebellar meninges showed that spores and hyphae were rapidly disseminated hematogeneously. This hematogeneous spreading probably explains the distribution of the cerebellar lesions, but the way of spreading might not be explained only by cerebellar location. Brain lesions in turkeys consisted of solitary abscesses with necrotic centers infiltrated with heterophils and surrounded by giant cells or granulomatous encephalitis (1,11). In our case, brain lesions observed in cerebellum and cerebellar meninges were malacic but not granulomatous in nature.

In conclusion, the present case has differences from the previously published cases in that, first, it is about an aspergillosis infection concurrently caused by *A. fumigatus* and *A. niger*, and second, it was observed in a broiler breeder flock as a chronic infection, and eventually the brain lesions confined to cerebellum and cerebellar meninges were malacic in nature.

REFERENCES

- Alexandrow, M., and A. Vesselinova. Durch *Aspergillus fumigatus fresenius* bei truthühnern verursachte meningoenzephalitis. Zentralbl. Veterinaer-med. Reihe B. 20:304-309. 1973.
- Barton, J. T., B. M. Daft, D. H. Read, H. Kinde, and A. A. Bickford. Tracheal aspergillosis in

- 6½-week-old chickens caused by *Aspergillus flavus*. *Avian Dis.* 36:1081–1085. 1992.
3. Beckman, B. J., C. W. Howe, D. W. Trampel, M. C. DeBey, J. L. Richard, and Y. Niyo. *Aspergillus fumigatus* keratitis with intraocular invasion in 15-day-old chicks. *Avian Dis.* 38:660–665. 1994.
 4. Dyar, P. M., O. J. Fletcher, and R. K. Page. Aspergillosis in turkeys associated with use of contaminated litter. *Avian Dis.* 28:250–255. 1983.
 5. Fitzgerald, S. D., and P. G. Moisan. Mycotic rhinitis in an ostrich. *Avian Dis.* 39:194–196. 1995.
 6. Luna, L. G., *Manual of histological staining methods of the Armed Forces Institutes of Pathology*, 3rd ed. McGraw Hill Book Company, New York. 1968.
 7. Okoye, J. O. A., H. C. Gugnani, and C. N. Okeke. Pulmonary infections due to *Aspergillus flavus* in turkey poult and goslings. *Mycoses* 32:336–339. 1988.
 8. Okoye, J. O. A., C. N. Okeke, and F. K. O. Ezeobele. Effect of infectious bursal disease virus infection on the severity of *Aspergillus flavus* aspergillosis of chickens. *Avian Pathol.* 20:167–171. 1991.
 9. Pal, M., S. Prajapati, and R. M. Gangopadhyay. *Aspergillus fumigatus* as a cause of mycotic tracheitis in a chicken. *Mycoses* 33:70–72. 1988.
 10. Perelman, B., and E. S. Kuttin. Aspergillosis in ostriches. *Avian Pathol.* 21:159–163. 1992.
 11. Raines, T. V., C. D. Kuzdas, F. H. Winkel, and B. S. Johnson. Encephalitic aspergillosis in turkeys—a case report. *J. Am. Vet. Med. Assoc.* 129:435–436. 1956.
 12. Richard, J. L. Aspergillosis. In: *Diseases of poultry*, 10th ed. B. W. Calnek, H. J. Barnes, C. W. Beard, W. M. Reid, and H. W. Yoder, Jr., eds. Iowa State University Press, Ames, IA. pp. 351–360. 1997.
 13. Richard, J. L., and J. R. Thurston. Rapid hematogenous dissemination of *Aspergillus fumigatus* and *A. flavus* spores in turkey poult following aerosol exposure. *Avian Dis.* 27:1025–1033. 1983.
 14. Singh, N., G. S. Grewal, R. S. Brar, B. Singh, A. S. Dhaliwal, and S. K. Jand. Outbreak of mycotic tracheitis in domestic fowl. *Mycoses* 36:65–67. 1993.
 15. Singh, H., G. S. Grewal, and N. Singh. Mycotic salpingitis in a Japanese quail (*Coturnix coturnix japonica*). *Avian Dis.* 38:910–913. 1994.
 16. van Veen, L., R. M. Dwars, and T. H. F. Fabri. Mycotic spondylitis in broilers caused by *Aspergillus fumigatus* resulting in partial anterior and posterior paralysis. *Avian Pathol.* 28:487–490. 1999.